



PATIENT

Rennie Thompson

SPECIES

Canine

BREED

Labrador Retriever

SEX

Male Neutered

AGE

10 years

WEIGHT

66.1lbs; 30kgs

INTERPRETED BY

Maggie Machen Lamy,
DVM, DACVIM
(Cardiology)

IMAGING PERFORMED BY

Melissa Weisman, DVM

HOSPITAL NAME

Minnesota Veterinary
Ultrasound

REFERRING VET

Dr. Weisman

INVOICE

30159

DATE

4/10/23

PRESENTING CLINICAL SIGNS

History: Patient has had a loud heart murmur noted by a previous veterinarian for multiple years, but no imaging or further work up was ever performed. On 1/11/23 a grade 4/6 left systolic heart murmur was noted at SPPH and an echocardiogram was recommended to assess the heart condition to determine if medications are needed. The patient received Gabapentin and Butorphanol.

ECHOCARDIOGRAM FINDINGS

2D, m-mode and Doppler imaging are available. Diffuse thickening of mitral valve leaflets (anterior > posterior) with no prolapse into the left atrial lumen. Severe eccentric mitral regurgitation with marked left atrial dilation. Lack of coaptation in systole. Significant LV dilation with depressed myocardial function due to volume overload. The tricuspid valve appears mildly thickened, with mild to moderate tricuspid regurgitation. Normal velocity. Mild right atrial and ventricular dilation most consistent with early pulmonary arterial hypertension. The pulmonic and aortic valves are normal in morphology and mobility. Normal pulmonic and aortic outflow velocities. No pulmonic and mild aortic insufficiency. No pericardial or pleural effusion noted. No cardiac tumors observed.

CARDIAC CHART

CANINE CARDIAC PARAMETERS	MR VMAX (m/s)	TR VMAX (m/s)	LA/AO (Boon method)	LA/AO (Heart Base; Swe)	FS (%)	EF (%)	EPSS (cm)
NORMAL PARAMETER	4.5-5.5	<2.7	1.3	<1.6	28-40	40-100	<0.6
PATIENT	4.8	2.0	NM	2.5	40	69	NM
CANINE CARDIAC PARAMETERS	HR (BPM)	AV VMAX (m/s)	PV MAX (m/s)	BODY WEIGHT (kg)	LA 2D short axis Base view (cm)	LVIDd Avg: 2D and m-mode short axis (cm)	LVIDs Avg: 2D and m-mode short axis (cm)
NORMAL PARAMETER	50-100	0.7-1.7	0.7-1.6	BELOW	BELOW	BELOW	BELOW
PATIENT	120	1.4	0.60	30.0	5.0	6.9	4.4
*Normal chamber parameters expressed as a mean value (SD)				3	1.27 (5.3)	2.46 (2.46)	1.36 (5.5)
BODY WEIGHT DEPENDENT PARAMETERS				5	1.40 (4.5)	2.74 (5.2)	1.60 (4.7)
<i>*Note: All measurements based upon multi-modal images and methods. An average value is reported.</i>				10	1.50 (3.8)	3.27 (3.5)	2.06 (3.1)
				15	1.83 (2.0)	3.71 (2.4)	2.43 (2.1)
				20	2.02 (1.9)	4.14 (2.2)	2.80 (2.0)
				25	2.18 (2.4)	4.48 (2.9)	3.10 (2.5)
				30	2.33 (3.3)	4.83 (3.9)	3.39 (3.4)
				35	2.48 (4.3)	5.17 (5.0)	3.69 (4.5)
				40	2.62 (5.2)	5.48 (6.1)	3.96 (5.4)
				50	2.88 (7.1)	6.07 (8.3)	4.46 (7.4)

INTERPRETATION OF THE FINDINGS & FURTHER RECOMMENDATIONS

The cause of the murmur is chronic degenerative valve disease causing severe mitral and mild to moderate tricuspid regurgitation. Marked left atrial enlargement indicates the risk for spontaneous congestive heart failure is elevated. Mild TR is also noted, with suspect early pulmonary hypertension. Finally, a small aortic insufficiency is appreciated, and a baseline BP is recommended. No additional issues are identified.



PATIENT

Rennie Thompson

SPECIES

Canine

BREED

Labrador Retriever

SEX

Male Neutered

AGE

10 years

WEIGHT

66.1lbs; 30kgs

INTERPRETED BY

Maggie Machen Lamy,
DVM, DACVIM
(Cardiology)

IMAGING PERFORMED BY

Melissa Weisman, DVM

HOSPITAL NAME

Minnesota Veterinary
Ultrasound

REFERRING VET

Dr. Weisman

INVOICE

30159

DATE

4/10/23

Even without symptoms, given the severity of disease seen here and exceedingly high risk for decompensation, full lifelong cardiac support is recommended as below including low-dose Lasix therapy. Cough suppression may also be useful if needed for QOL. Monitoring of sleeping breathing rates in the future will be paramount to determine the origin of any future cough. The average survival of canine patients with active pulmonary edema is 8-9 months on medications, however they generally are able to maintain a good quality of life for that period. Patient will always be at risk for recurrent CHF, development of arrhythmias/LA tear, syncope and/or sudden death in the future. Monitoring of renal values is recommended lifelong.

Elective anesthesia is not advised, as there is high risk for complication. Risk: benefit ratio should be considered. Consider consultation with and/or referral to a facility with an anesthesiologist. Should you elect to proceed, cardiac protective drug choices (opioid/benzodiazepine premedication, propofol or alfaxalone induction, iso or sevoflurane gas) are recommended. Pre-oxygenate for 5-10 minutes prior to induction and recover in O₂ cage. Monitor for arrhythmias, hypotension, and hypoxia both intra and post-operatively and intervene as necessary. Moderate IV fluid restriction is recommended to avoid fluid overload, while considering comorbidities, hydration status, BP, etc. Avoid heart rate stimulating drugs such as atropine unless clinically indicated.

Omega fatty acid supplementation and mild salt restriction may also be of some long term benefit. Monitor for development of a worsening cough, labored breathing, exercise intolerance or collapse episodes.

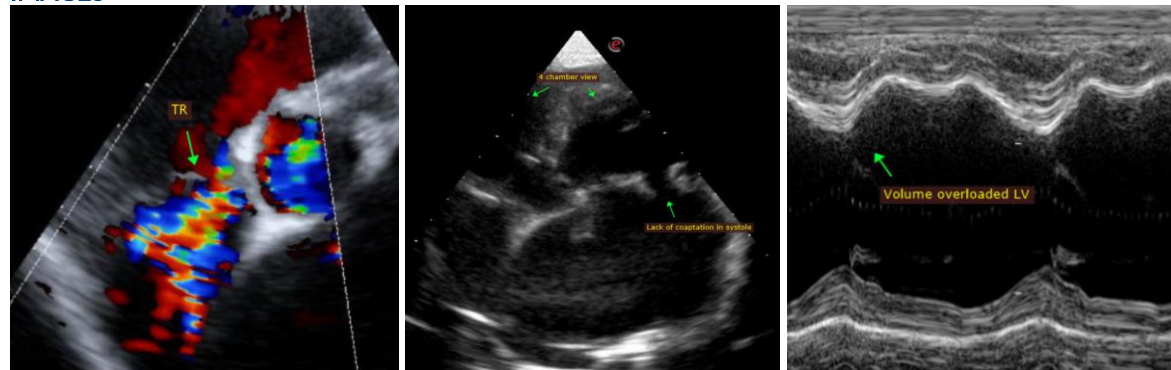
PLAN

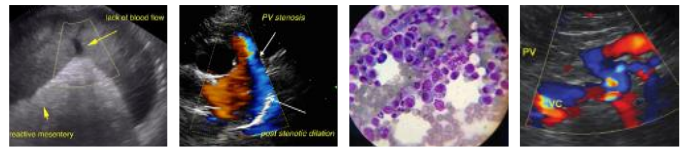
Screening BP, CXR and ECG are recommended. Administer Pimobendan 0.3mg/kg PO q12h. Administer low dose furosemide/Lasix 1 mg/kg PO q12h. Administer spironolactone 1-2mg/kg PO q12h. Consider hydrocodone with homatropine (0.2-0.4mg/kg PO up to q4-6 hours PRN) if cough persists despite normal SRRs.

A renal panel and BP are recommended in 10-14 days, then every 3-4 months on diuretics to ensure tolerance of medications. If doing well at that time and BP >130mmHg, institute ACEI 0.5mg/kg PO q12h.

A recheck echocardiogram is recommended in 6 months to screen for progression, sooner if clinical signs arise/persist.

IMAGES





PATIENT

Rennie Thompson

The information and recommendations provided are based on the images presented by the referring veterinarian. No evaluation can be communicated regarding pathology that was not visible in the image/video clips provided.

SPECIES

Canine

Thank you for this referral. This report was generated using transcription software, and minor dictation errors may be present. If the clinical or image interpretation does not parallel your findings or if I can be of any further assistance, please contact me.

BREED

Labrador Retriever

Maggie Machen Lamy, DVM
Diplomate of the American College of Veterinary Internal Medicine (Cardiology)
info@sonopath.com

SEX

Male Neutered

AGE

10 years

WEIGHT

66.1lbs; 30kgs

INTERPRETED BY

Maggie Machen Lamy,
DVM, DACVIM
(Cardiology)

**IMAGING
PERFORMED BY**

Melissa Weisman, DVM

HOSPITAL NAME

Minnesota Veterinary
Ultrasound

REFERRING VET

Dr. Weisman

INVOICE

30159

DATE

4/10/23